

# *Phialemonium*: An Emerging Mold Pathogen That Caused 4 Cases of Hemodialysis-Associated Endovascular Infection

Laurie A. Proia,<sup>1</sup> Mary K. Hayden,<sup>1</sup> Patricia L. Kammeyer,<sup>2</sup> Joanna Ortiz,<sup>3</sup> Deanna A. Sutton,<sup>4</sup> Thomas Clark,<sup>5</sup> Hans-Josef Schroers,<sup>6</sup> and Richard C. Summerbell<sup>6</sup>

<sup>1</sup>Rush University Medical Center, Chicago, <sup>2</sup>Loyola University Medical Center, Maywood, and <sup>3</sup>West Suburban Hospital, Oak Park, Illinois; <sup>4</sup>Fungus Testing Laboratory, University of Texas Health Science Center at San Antonio; <sup>5</sup>Mycotic Diseases Branch, Centers for Disease Control and Prevention, Atlanta, Georgia; and <sup>6</sup>Centraalbureau voor Schimmelcultures Fungal Biodiversity Center, Utrecht, The Netherlands.

*Phialemonium* species are emerging as fungal opportunistic pathogens of humans; infections caused by these fungi often have a fatal outcome. We report a series of 4 patients undergoing chronic hemodialysis who developed intravascular infection with *Phialemonium curvatum*. All isolates were of a distinct morphological type but were shown by partial ribosomal sequencing to be closely related to reference isolates of *P. curvatum*. Two patients in our case series died; both developed overwhelming infection associated with fungemia and endocarditis. Recent literature corroborates our experience that *Phialemonium* infection presents unique diagnostic challenges and that optimal management, particularly with regard to antifungal therapy, is not known.

The dematiaceous or melanized fungi, once thought to possess low pathogenic potential, have become increasing causes of severe and disseminated infections in immunocompromised individuals. *Phialemonium*, considered to be a dematiaceous fungus by most authorities, although it lacks conspicuous dark pigmentation, was originally described as a genus intermediate between the *Acremonium* and *Phialophora* genera [1]. It once included 3 species—*Phialemonium curvatum*, *Phialemonium obovatum*, and *Phialemonium dimorphosporum*—but *P. dimorphosporum* was later synonymized with *P. curvatum* [2]. Distributed widely in the environment, *Phialemonium* species have been isolated from air, soil, industrial water, and sewage [1]. Although these species rarely cause human disease, infection is often fatal [2–8]. We present 4 patients undergoing chronic hemodialysis who developed intravascular in-

fection with an atypical variant of *P. curvatum*. Our findings suggest that this species may be a potential emerging pathogen in patients undergoing dialysis.

## CASE REPORTS

**Patient 1.** A 35-year-old man with chronic renal failure presented to the hospital with a 1-month history of right ocular pain, swelling, and vision loss. One year before presentation, the patient underwent cadaveric renal transplantation, but he developed acute rejection and allograft failure 1 month after surgery. The patient continued to receive low-dose oral prednisone (5 mg/day) and cyclosporine for 10 months after surgery. Hemodialysis was resumed via an arteriovenous (AV) fistula.

The patient received a diagnosis of chorioretinitis. The prednisone dosage was increased to 80 mg/day. He had no improvement in vision after 2 weeks, and vitreal aspiration was performed. Gram staining demonstrated both hyphal and yeast-like forms, and the patient was hospitalized with a diagnosis of fungal endophthalmitis. Amphotericin B deoxycholate therapy was begun (1 mg/kg per day), and blood cultures were performed

Received 5 December 2003; accepted 11 March 2004; electronically published 9 July 2004.

Reprints or correspondence: Dr. Laurie A. Proia, Section of Infectious Diseases, Rush University Medical Center, 600 S. Paulina, Ste. 143 AAC, Chicago, IL 60612 (lproia@rush.edu).

**Clinical Infectious Diseases** 2004;39:373–9

© 2004 by the Infectious Diseases Society of America. All rights reserved.  
1058-4838/2004/3903-0013\$15.00

(BacT/ALERT, aerobic and anaerobic bottles; bioMérieux). Physical examination revealed that the patient was afebrile, and inspection of the right eye was notable for periorbital edema, scleral injection with hemorrhagic foci, and vitreal clouding. Cardiac auscultation revealed a grade II/VI systolic ejection murmur. Results of examination of the AV fistula site were normal. A transesophageal echocardiogram (TEE) demonstrated large vegetations on both mitral and aortic valves, with associated valvular insufficiency. Results of blood cultures became positive after 4 days of incubation. Subculture of the positive blood cultures (incubated at 35°C) and primary culture of the vitreal fluid (incubated at 30°C) showed heavy growth of mold after 72 h of incubation. The mold was classified initially as an *Acremonium* species but further analysis suggested *Phialemonium* species. The dosage of amphotericin B deoxycholate was increased to 1.5 mg/kg per day, and caspofungin (70-mg loading dose, then 50 mg/day) was added to the regimen. The patient underwent combined aortic and mitral valve replacement and right eye vitrectomy. During surgery, vegetations were seen on the anterior and posterior leaflets of the mitral valve and on all leaflets of the aortic valve. A valve-ring abscess on the posterior leaflet of the mitral valve was debrided. Both valves were replaced with St. Jude Medical mechanical prostheses. Intravitreal amphotericin B deoxycholate (10 µg in 100 µL of normal saline) was instilled into the right eye. Gram staining of mitral valve tissue revealed septate hyphae, and cultures of mitral and aortic valve tissue specimens grew *P. curvatum*, as did culture of vitreous fluid.

On day 1 after the operation, the patient became febrile and hypotensive. He developed acute congestive heart failure and disseminated intravascular coagulation and then died. Cultures of blood samples obtained after the operation grew *P. curvatum*. Postmortem examination revealed cardiomegaly and marked left ventricular dilatation. A large vegetation had overgrown the prosthetic mitral valve and had invaded through the left ventricular wall. Splenomegaly and a large splenic abscess were also noted.

**Patient 2.** A 66-year-old man undergoing long-term hemodialysis was hospitalized for purulent drainage arising from a nonfunctioning AV graft site. This graft had thrombosed and had not been used for 3 years. Eleven months earlier, the patient had 2 routine blood cultures performed during hemodialysis that grew *P. curvatum* (aerobic bottles). The patient was clinically healthy, and results of additional blood cultures were negative. The isolated strain of *P. curvatum* was considered to be a contaminant, and the patient received no antifungal therapy.

At the time of admission to the hospital, the patient was afebrile. A soft systolic murmur over the cardiac apex was noted. Examination of the AV graft site revealed erythema, warmth, tenderness, and purulent drainage. The patient un-

derwent immediate resection of the graft. Three blood cultures and a graft tissue specimen culture grew *P. curvatum*. Treatment was begun with amphotericin B deoxycholate (1.5 mg/kg per day) and intravenous fluconazole (800 mg loading dose, then 400 mg/day). TEE showed a small, calcified vegetation on the anterior leaflet of the mitral valve that extended into the left atrium, with mild mitral regurgitation. No abnormal retinal findings were detected, and results of additional blood cultures were negative. Valve replacement surgery was postponed, given the chronic appearance of the mitral valve vegetation, absence of hemodynamic compromise, and negative blood culture results. Medical management with amphotericin B deoxycholate and fluconazole was continued. Nine days later, the patient died after being found unresponsive in the hospital. No autopsy was performed.

**Patient 3.** A 70-year-old woman undergoing long-term hemodialysis was hospitalized for a malfunctioning AV graft. Her medical history included cerebrovascular accident, type II diabetes mellitus, and peripheral vascular disease. She was hospitalized for surgical removal of the graft and placement of a temporary hemodialysis catheter. In the operating room, purulent drainage was noted at the venous anastomosis site of the graft, and the graft was resected. The patient's postoperative course was uncomplicated. She was discharged home receiving no antibiotics. Subsequently, growth of a *Phialemonium* species was observed on culture of a graft tissue specimen. The patient was readmitted and treated with amphotericin B deoxycholate (1 mg/kg per day). She was afebrile, and findings of examination of her surgical wound were unremarkable. Results of blood cultures were negative, TEE showed no evidence of endocarditis, and findings of ophthalmologic examination were normal. After 12 days of treatment with amphotericin B deoxycholate, the patient was discharged receiving oral voriconazole (2 loading doses of 400 mg, then 200 mg every 12 h). She died 2 months later after experiencing an unrelated traumatic injury.

**Patient 4.** A 77-year-old man with type II diabetes mellitus and chronic renal failure requiring hemodialysis was admitted to hospital with fever. He had no other focal symptoms or signs of infection, and his AV graft site appeared to be normal. Results of blood cultures were negative after 48 h of incubation, and the patient was discharged home. He was readmitted 1 week later after 2 of the blood cultures grew a fungus. He was treated initially with amphotericin B deoxycholate (1 mg/kg per day). The initial yeast-like blood culture isolate was identified as a strain of *Phialemonium* species, and oral voriconazole (2 loading doses of 400 mg, then 200 mg every 12 h) was added. Results of additional blood cultures were negative, findings of ophthalmologic examination were normal, and there were no abnormal findings on a TEE. Ultrasonography of the AV graft revealed new thrombosis, and, because the graft was considered to be the likeliest source of fungemia, it was resected. Histo-

pathologic examination of resected graft material showed inflammatory cells and numerous fungal elements, and culture of the AV graft grew *Phialemonium* species. Episodes of fever recurred, and a second TEE revealed a 1.2-cm vegetation on the posterior leaflet of the mitral valve. Combination antifungal therapy with intravenous amphotericin B deoxycholate and oral voriconazole was continued for 1 month, followed by voriconazole monotherapy for 2 additional months. A TEE performed at the end of antifungal treatment showed no valvular vegetations.

## METHODS

*Phialemonium* isolates from 4 patients were identified during an 18-month period (February 2001 through August 2002). The isolates were received on Sabouraud agar (Becton Dickinson), subcultured on potato flakes agar (Remel), and incubated at 30°C. After preliminary identification of *Phialemonium* species was reported, the isolates were referred to the Fungus Testing Laboratory at the University of Texas Health Science Center at San Antonio (UTHSCSA). Isolates from patients 1–4 were accessioned into the UTHSCSA stock collection as 01-1853, 01-1959 and 02-127 (patient 2 had 2 isolates corresponding to each episode of fungemia; a new accession number was assigned to the first isolate for retrospective antifungal susceptibility testing), 02-1552, and R-3471, respectively. They were morphologically identified as *P. curvatum* on the basis of results of culture on potato flakes agar (prepared in-house) at 25°C.

The isolates were evaluated for susceptibility to antifungal agents using standardized, approved methodology for macrobroth dilution testing [9]. In brief, a final inoculum of  $0.4 \times 10^4$ – $5 \times 10^4$  cfu/mL was used for test isolates and the *Paecilomyces variotii* control strain UTHSC 90-459, and incubation was performed at 35°C. RPMI 1640 medium (Angus Buffers and Biochemicals) was used to test for susceptibility to itraconazole (Janssen Research Foundation), fluconazole, voriconazole (Pfizer), and posaconazole (Schering-Plough), as well as to 5-flucytosine (Roche Laboratories). Antibiotic medium 3 was used to test for susceptibility to amphotericin B deoxycholate (Bristol-Myers Squibb) and caspofungin (Merck). End points for caspofungin corresponded to the minimum effective concentration (MEC), as defined by Kurtz et al. [10] in 1994 and Arikan et al. [11] in 2001. Synergy testing was conducted by means of a macrobroth checkerboard format [9].

All isolates were sent to the Centraalbureau voor Schimmelmcultures (CBS; Utrecht, The Netherlands) for further study and molecular analysis. At CBS, the isolates were grown on malt extract agar and oatmeal agar and were studied morphologically after 7 and 14 days of incubation at 21°C.

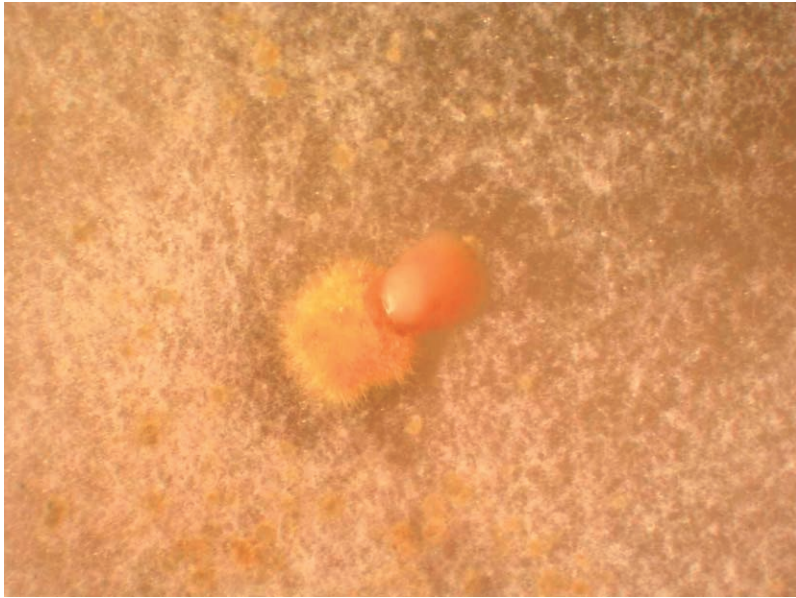For molecular study, the fungi were grown on liquid complete yeast medium. DNA was extracted using the FastDNA Kit (Bio 101) in accordance with the manufacturer's instruc-

tions. Amplification was performed using primers V9G/LR5 [12, 13] designed to span the internal transcribed spacer (ITS) region of nuclear ribosomal DNA. A PCR System 9700 machine (PE Applied Biosystems) programmed with the ramp speeds of the PCR System 9600 was used for amplification. The PCR program involved an initial denaturation step at 94°C for 2 min, followed by 35 cycles at 94°C for 35 s, 55°C for 50 s, and 72°C for 2 min, and then by a final extension at 72°C for 6 min. The reaction mixtures of 50  $\mu$ L contained 1  $\mu$ L of genomic DNA extract, 25 pmol of each primer, 200  $\mu$ mol of each dNTP (Amersham Pharmacia Biotech), 1 U of Taq polymerase (Super Taq; HT Biotechnology), and 1 $\times$  standard PCR buffer that was supplied with the Taq polymerase. After purification of the PCR products with the GFX PCR DNA and Gel Band Purification Kit (Amersham Pharmacia) and verification of the final concentration, PCR products were sequenced with the primers ITS1 and ITS4 [14] by means of the BigDye terminator cycle sequencing kit (Applied Biosystems). Sequences were analyzed on an ABI Prism 3700 instrument (Applied Biosystems).

New and published sequences were aligned using Clustal X, version 1.81 [15]. Phylogenetic relationships of the taxa were estimated from the aligned sequences by the maximum parsimony criterion, as implemented in PAUP, version 4.0b10 [16]. Heuristic searches were performed using parsimony informative, unordered, and equally weighted characters; branch robustness was tested by means of 1000 search replications, each on bootstrapped data sets. Gaps were treated as missing characters. Starting tree(s) were obtained via stepwise, random sequence addition repeated 100 times (repeated 10 times in bootstrap analyses). A maximum number of 9000 trees (1000 trees in bootstrap analyses) were allowed. Newly generated DNA sequences have been deposited in GenBank (accession numbers AY464124–AY464131).

## RESULTS

After a 7-day incubation on Sabouraud-dextrose agar, case isolates were cream to yellowish in color and floccose, with a diameter of 25–30 mm. At 14 days, the color of the isolates became gun-metal gray with a white edge. Microscopic evaluation revealed that the fungus produced basally septate phialides (length, 10–16  $\mu$ m) and basally aseptate adelopialides (length, 2–7  $\mu$ m), which bore mucoid clusters of conidia. Conidia were hyaline, had a size of 4–5  $\times$  2–3  $\mu$ m, and were subglobose to ellipsoidal or curved. On oatmeal agar, after  $\sim$ 10 days, the case isolates developed distinctive sporodochial structures not previously reported for *P. curvatum* (figure 1). A sporodochium is a macroscopically visible, cushion-like mass of short conidiophores bearing conidia. Sporodochia were  $\sim$ 1.5 mm in diameter and cup-shaped, sometimes with a constricted aperture, and they had an exterior covering of golden-brown,

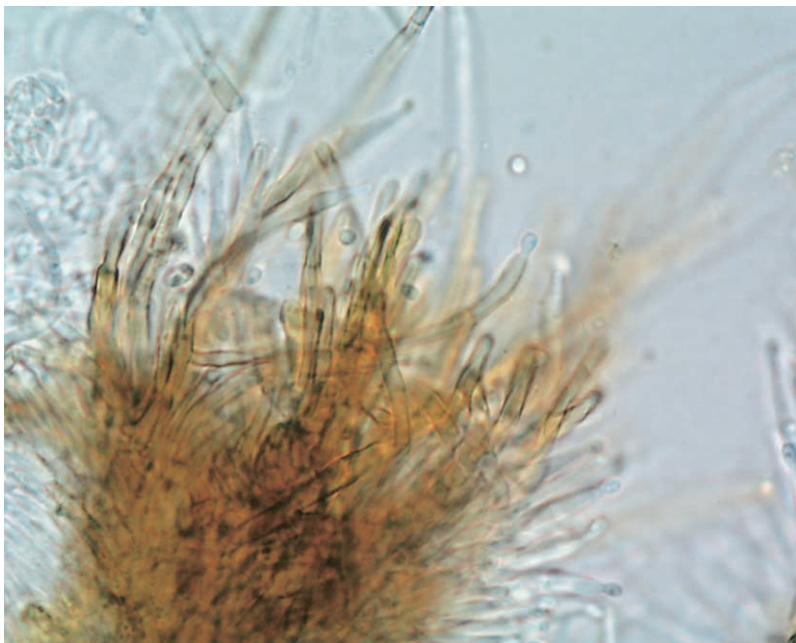


**Figure 1.** A dissection microscope view of a typical sporodochium (diameter, ~1 mm) formed by a morphologically atypical *Phialemonium curvatum* isolate discussed in the present study.

stiff, spiny hairs and an interior filled with yellow, mucoid conidia. They often opened apically, but lateral openings were also common (figure 1). Microscopic examination showed that the inner sporodochial surfaces were composed of stiff, frequently rebranching hyphae that were brownish in their lower, thicker regions, with tapered discrete and intercalary phialides (figure 2). Conidia formed in sporodochia had an ellipsoidal

to ovoidal shape, were generally not curved, and, with a size of  $2.0\text{--}3.3 \times 1.2\text{--}1.8 \mu\text{m}$ , were smaller than hyphal conidia.

After development of sporodochia, organisms grown on the cultures at first appeared to be members of *Volutella*, a genus known to cause human opportunistic infections [17, 18]. After sequencing showed that the isolates were related to *P. curvatum*, the ex-type strain (CBS 490.82) and reference isolates of this



**Figure 2.** A portion of a *Phialemonium curvatum* sporodochium from a case isolate (Centraalbureau voor Schimmelcultures collection number 110656), showing hyaline phialides and also sporulation of dark seta-like phialides (lactic acid–cotton blue preparation; original magnification,  $\times 1000$ ).

species were restudied. Consistent with the original description of *P. curvatum* [1], the isolates failed to produce sporodochial structures. The only available *Volutella* isolate associated with human infection—CBS 832.71, which is an agent of endophthalmitis [18]—was therefore studied. This isolate had a morphology that was more closely similar to that of the current case isolates than did any *Phialemonium* isolate. It produced a *P. curvatum*-like synanamorph and had an ITS sequence consistent with placement in the *P. curvatum* complex (figure 3). Overall, it was observed that some but not all isolates genetically corresponding to *P. curvatum* are able to produce sporodochial structures mimicking *Volutella* species and that this characteristic may be present in potentially related case isolates, such as those in the present study.

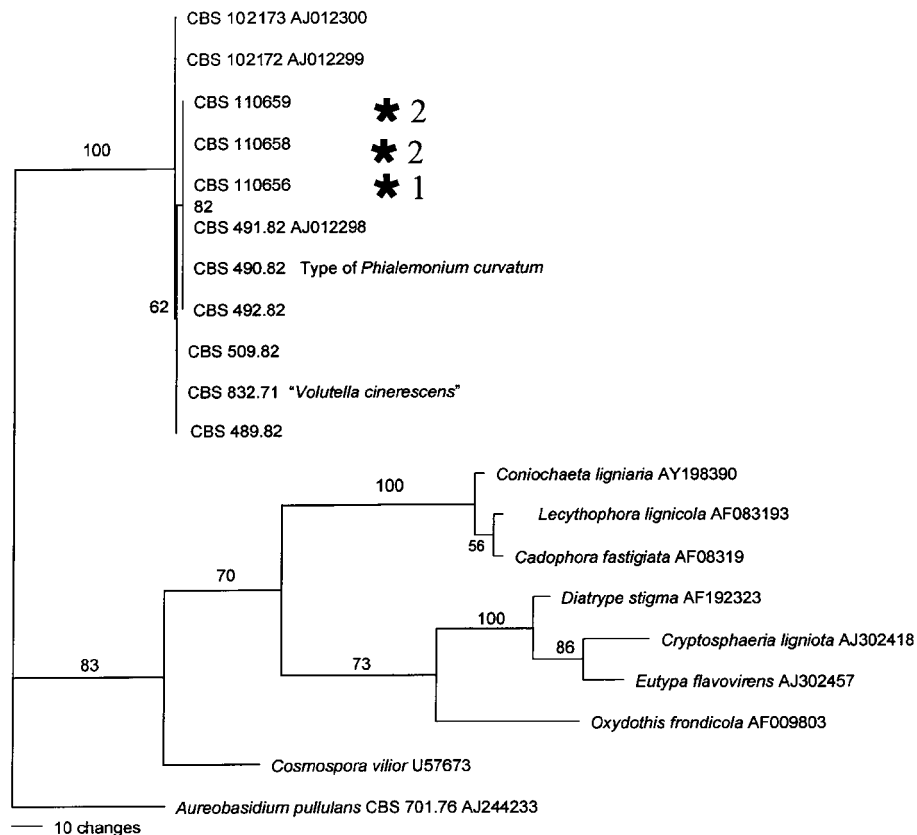
During sequencing, heuristic parsimony analyses of 207 parsimony informative characters resulted in a single most-parsimonious tree, with a length of 497 steps, a consistency index of 0.738, and a retention index of 0.830. The case isolates had ITS sequences that were identical to each other and to the ex-type isolate of *P. curvatum*. They clustered strongly with other

*P. curvatum* strains, including strains originally identified as *P. dimorphosporum* (figure 3).

The 4 case isolates differed insignificantly from each other with respect to antifungal susceptibility (table 1). MICs of amphotericin B deoxycholate were high, whereas those of fluconazole and itraconazole were intermediate. Voriconazole and posaconazole had low MICs. Caspofungin MECs were high, but caspofungin combined with amphotericin B deoxycholate appeared to have an additive effect.

## DISCUSSION

These 4 cases of hemodialysis-associated endovascular infection caused by *P. curvatum* reveal new pathogenic capabilities of this organism. Patient 1 continued to receive long-term immunosuppressive therapy despite failure of renal transplantation, and this may have contributed to relatively fulminant illness. This patient presented with endophthalmitis, which was likely a result of hematogenous seeding during fungemia or septic embolization secondary to left-sided endocarditis. Autopsy re-



**Figure 3.** Most parsimonious tree showing members of the *Phialemonium curvatum* complex and the most closely related species, with outgroups made monophyletic. For statistical analysis, see Results. Centraalbureau voor Schimmelcultures (CBS) collection numbers begin with “CBS”; all other numbers are GenBank accession numbers. Two isolates from patient 2 represent earlier and later isolates, as described in Case reports, showing consistency of the strain involved. Isolates from patients 3 and 4 were identical in sequence to those from patients 1 and 2 and are therefore not shown.

**Table 1. In vitro antifungal susceptibility testing of *Phialemonium* isolates from case patients.**

Drug tested, by study type	Value after 48 h, $\mu\text{g/mL}$			
	Patient 1	Patient 2	Patient 3	Patient 4
Individual drug studies				
Amphotericin B, MIC	2	2	2	2
5-flucytosine, MIC	>64	ND	ND	ND
Fluconazole, MIC	16	>16	16	16
Itraconazole, MIC	0.25	0.5	0.25	0.25
Voriconazole, MIC	0.25	0.25	0.25	0.25
Posaconazole, MIC	0.06	0.125	0.125	0.125
Caspofungin, MEC	16	>32	>16	>16
Combined drug studies <sup>a</sup>				
Amphotericin B plus caspofungin				
MIC + MEC	1 + $\leq 0.125$	1 + $\leq 0.125$	ND	ND
MLC + MLC	1 + $\leq 0.125$	1 + 8	ND	ND
Amphotericin B plus fluconazole				
MIC + MIC	ND	2 + $\leq 0.125$	ND	ND
MLC + MLC	ND	>2 + >16	ND	ND

**NOTE.** Analyses were performed by Dora McCarthy, courtesy of the Fungus Testing Laboratory, Department of Pathology, The University of Texas Health Science Center at San Antonio. MEC, minimum effective concentration (as defined in [10, 11]); MLC, minimum lethal concentration; ND, not done.

<sup>a</sup> The combination of amphotericin B and caspofungin appeared to be additive for each isolate, whereas the combination of amphotericin B and fluconazole for the isolate of patient 2 appeared to be indifferent.

vealed that the prosthetic mitral valve was overgrown with fungal vegetations within days after surgery. This suggests that *Phialemonium* organisms can be highly virulent pathogens and that endovascular invasion may be a prominent feature of infection.

Patient 2 received a diagnosis of 2 episodes of *Phialemonium* fungemia that occurred 11 months apart. The first episode resolved without therapy, and pseudofungemia was suspected. In fact, this patient may have harbored *Phialemonium* infection for  $\geq 11$  months. The infection may have been contained within the thrombosed fistula because of a relative lack of blood flow to that area. Slow growth of the organism may have continued until a critical burden was reached, at which time fungemia and endocarditis developed.

It should be emphasized that, in our cases, *Phialemonium* organisms were able to grow in routine blood culture bottles, suggesting that routine culture methods may be sufficient for isolation of this mold. *Phialemonium* was often mistaken for yeast on Gram stains of blood specimens. These yeast-like forms were likely free conidia or spores of *Phialemonium* species. Similar phenomena have been observed in human cases of infection caused by the molds *Fusarium* and *Acremonium*. Formation of yeast-like cells may facilitate hematogenous dissemination and could explain recovery of *Phialemonium* in automated blood culture systems [19].

All 4 cases of *Phialemonium* infection were identified during an 18-month period, including the 2 episodes of fungemia that

occurred in patient 2. It is also interesting to note that all of our patients were dialyzed at the same hemodialysis unit, which suggests possible health care-associated exposure to *Phialemonium* species.

Two of our patients were treated with combinations of high-dose amphotericin B deoxycholate and either caspofungin or intravenous fluconazole, and both died. Two of our patients survived. Of interest, both patients who survived were treated with voriconazole. However, it is unclear what, if any, role antifungal therapy played in each of these cases, because resection of infected graft material may have been curative. Voriconazole and posaconazole appeared to have low MICs against *Phialemonium* organisms, but the clinical efficacy of these agents for treating *Phialemonium* infection is currently unknown.

To our knowledge, 13 cases of human *Phialemonium* infection have been reported to date, including our cases [2–8]. Two cases of *Phialemonium* osteomyelitis in German shepherd dogs have also been reported [20, 21]. The first published case of disseminated *Phialemonium obovatum* infection occurred in 1976 in a 5-month-old child with severe skin burns [3]. Examination of wound tissue specimens revealed fungal elements, and burn wounds were debrided. No antifungal treatment was given, and the patient died. Postmortem examination resulted in the first appreciation of the propensity for this organism to invade viable tissue and blood vessels. *Phialemonium* organisms have also been associated with lumbar osteomyelitis/diskitis

after nonpenetrating back trauma [4], mycetoma in a renal transplant recipient [5], mycetoma in a bone marrow transplant recipient [6], and peritonitis in a pediatric renal transplant recipient with a retained peritoneal dialysis catheter [5]. Two prior cases of *Phialemonium* fungemia have been reported [2]. Both patients had underlying hematologic malignancies, neutropenic fever, and fungemia possibly associated with central venous catheter infection. One patient, in whom neutropenia resolved and treatment with catheter removal and oral itraconazole was given, survived. Reports of 2 cases of *Phialemonium* endocarditis have been published [7, 8]. Aortic valve endocarditis occurred in a 63-year-old woman 7 months after valve replacement surgery [7]. Multiple blood cultures grew *Streptococcus sanguis* and *P. curvatum*, both of which were identified postmortem. No antifungal therapy was given. Native tricuspid valve endocarditis secondary to *P. obovatum* was reported in a 7-week-old premature infant who required prolonged hospitalization [8]. The boy died, despite receiving treatment with high-dose liposomal amphotericin B deoxycholate and surgical debridement of the tricuspid valve.

Eleven (85%) of these 13 patients who developed *Phialemonium* infection were immunocompromised, and the most common underlying conditions were chronic renal failure, renal transplantation, hematologic malignancy, and bone marrow transplantation. Seven (54%) of 13 survived *Phialemonium* infection, including 2 of our own patients. Of these 7 patients, 4 had disease confined to skin and/or soft tissue, to bone, or to the peritoneum. Nine (69%) of 13 patients developed *Phialemonium* fungemia, and 7 (78%) of these 9 fungemic episodes were associated with endocarditis. Seven (78%) of 9 patients with fungemia died, and 6 (86%) of 7 patients who had endocarditis died.

Despite a limited number of cases, the following pattern of *Phialemonium* infection in immunocompromised patients is beginning to emerge: possible health care-associated acquisition, endovascular infection, often with endocarditis and positive blood culture results, and a high mortality rate despite aggressive medical and surgical therapy. No single antifungal agent has been found to be particularly effective in treating *Phialemonium* infection. Absence of neutropenia or other immunosuppressing conditions may be important host factors for survival.

We predict that *Phialemonium* infections may be identified with increasing frequency. We should seek to determine environmental niches for this pathogen and other host risk factors for infection. We must attempt to correct underlying defects in host immunity when possible. Finally, if we can improve delays in microbiologic identification and learn which antifungal agents will be most effective therapeutically, we may improve the outcome of patients with *Phialemonium* infection.

## Acknowledgment

*Conflict of interest.* All authors: No conflict.

## References

- Gams W, McGinnis MR. *Phialemonium*, a new anamorph genus intermediate between *Phialophora* and *Acremonium*. *Mycologia* **1983**;75:977–87.
- Guarro J, Nucci M, Akiti T, et al. *Phialemonium* fungemia: two documented nosocomial cases. *J Clin Microbiol* **1999**;37:2493–7.
- McGinnis MR, Gams W, Goodwin MN. *Phialemonium obovatum* in a burned child. *J Med Vet Mycol* **1986**;24:51–5.
- Magnon KC, Jalbert M, Padhye AA. Osteolytic phaeohyphomycosis caused by *Phialemonium obovatum*. *Arch Pathol Lab Med* **1993**;117:841–3.
- King D, Pasarell L, Dixon DM, McGinnis MR, Merz WG. A phaeohyphomycotic cyst and peritonitis caused by *Phialemonium* species and a re-evaluation of its taxonomy. *J Clin Microbiol* **1993**;31:1804–10.
- Heins-Vacari EM, Machado CM, Saboya RS, et al. *Phialemonium curvatum* infection after bone marrow transplantation. *Rev Inst Med Trop São Paulo* **2001**;43:163–6.
- Schonheyder HC, Jensen HE, Gams W, et al. Late bioprosthetic valve endocarditis caused by *Phialemonium curvatum* and *Streptococcus sanguis*: a case report. *J Med Vet Mycol* **1996**;34:209–14.
- Gavin PJ, Sutton DA, Katz BZ. Fatal endocarditis caused by the dematiaceous fungus *Phialemonium obovatum*: case report and review of the literature. *J Clin Microbiol* **2002**;40:2207–12.
- NCCLS. Reference method for broth dilution antifungal susceptibility testing of filamentous fungi; approved standard. NCCLS document M38-A. Wayne, PA: NCCLS, **2002**.
- Kurtz MB, Heath IB, Marrinan J, Dreikorn S, Anishi J, Douglas C. Morphological effects of lipopeptides against *Aspergillus fumigatus* correlate with activities against (1,3)- $\beta$ -D-glucan synthase. *Antimicrob Agents Chemother* **1994**;38:1480–9.
- Arikan S, Lozano-Chiu M, Paetznick V, Rex JH. In vitro susceptibility testing methods for caspofungin against *Aspergillus* and *Fusarium* isolates. *Antimicrob Agents Chemother* **2001**;45:327–30.
- de Hoog GS, Gerrits van den Ende AH. Molecular diagnostics of clinical strains of filamentous basidiomycetes. *Mycoses* **1998**;41:183–9.
- Vilgaly R, Hester M. Rapid genetic identification and mapping of enzymatically amplified ribosomal DNA from several *Cryptococcus* species. *J Bacteriol* **1990**;172:4238–46.
- White TJ, Burns T, Lee S, Taylor J. Amplification and direct sequencing of fungal ribosomal RNA genes for phylogenies. In: Innis MA, Gelfand DH, Sninsky JJ, White TJ, eds. *A guide to methods and amplifications*. San Diego, CA: Academic Press, **1990**:315–322.
- Jeanmougin F, Thompson JD, Gouy M, Higgins DG, Gibson TJ. Multiple sequence alignment with Clustal X. *Trends Biochem Sci* **1998**;23:403–5.
- Swofford D. PAUP (phylogenetic analysis using parsimony) version 4.0 software. Sunderland, MA: Sinauer Associates, **2002**.
- de Hoog GS, Guarro J, Gené J, Figueras MJ. *Atlas of clinical fungi*. 2nd ed. Utrecht, The Netherlands: Centraalbureau voor Schimmeltculturen, **2000**.
- Summerbell RC. *Aspergillus*, *Fusarium*, *Sporothrix*, *Piedraia* and their relatives. In: Howard DH, ed. *Pathogenic fungi in humans and animals*. 2nd ed. New York: Marcel Dekker Press, **2003**:237–498.
- Schell WA, Perfect JR. Fatal disseminated *Acremonium strictum* infection in a neutropenic host. *J Clin Microbiol* **1996**;34:1333–6.
- Lomax LG, Cole JR, Padhye AA, Ajello L, Chandler FW, Smith BR. Osteolytic phaeohyphomycosis in a German shepherd dog caused by *Phialemonium obovatum*. *J Clin Microbiol* **1986**;23:987–91.
- Smith AN, Spencer JA, Stringfellow JS, Vygantas KR, Welch JA. Disseminated infection with *Phialemonium obovatum* in a German shepherd dog. *JAVMA* **2000**;216:708–12.